

Dealing with specialist pathology: an unusual case of ovarian hyperstimulation syndrome managed in the emergency department with point of care ultrasound

Roberto Lazzari, Mariona Condom Siñol

Emergency Department, Hospital de la Santa Creu i Sant Pau, Barcelona, Spain

Abstract

Ovarian hyperstimulation syndrome (OHSS) is a well-known complication of assisted reproduction. The hyperstimulated ovaries release vasoactive substances that can increase capillary permeability, resulting in volume shift to the extravascular space and leading to hypovolemia, ascites and, in complicated cases, pleural and pericardial effusions, kidney and liver failure, shock.

Point Of Care UltraSound (POCUS) can help the emergency physician to detect many of these complications, as well as guide their treatment. In this case report we present a patient at low risk for OHSS who recently underwent a successful in vitro fertilization, coming to the emergency department with an unusual complication of OHSS (an isolated pleural effusion), that has been safely and promptly diagnosed and treated in the emergency room with the help of POCUS, without any unnecessary exposition to ionizing radiations.

Correspondence: Roberto Lazzari, Servei d'Urgències. Planta D -1. Hospital de la Santa Creu i Sant Pau. Carrer de Sant Quintí, 89. 08025 Barcelona, Spain.
Tel.: +34672969953.
E-mail: rlazzari@santpau.cat

Key words: ovarian hyperstimulation, POCUS, pleural effusion.

Conflict of interest: the authors declare no potential conflict of interest, and all authors confirm accuracy.

Ethics approval and consent to participate: no ethical committee approval was required for this case report by the Department, because this article does not contain any studies with human participants or animals. Informed consent was obtained from the patient included in this study.

Patient consent for publication: the patient gave her written consent to use her personal data for the publication of this case report and any accompanying images.

Availability of data and materials: all data underlying the findings are fully available.

Received: 16 September 2023.

Accepted: 20 October 2023.

Publisher's note: all claims expressed in this article are solely those of the authors and do not necessarily represent those of their affiliated organizations, or those of the publisher, the editors and the reviewers. Any product that may be evaluated in this article or claim that may be made by its manufacturer is not guaranteed or endorsed by the publisher.

©Copyright: the Author(s), 2023

Licensee PAGEPress, Italy

Advances in Anesthesia and Pain Medicine 2023; 1:31

doi:10.4081/aapm.31

This work is licensed under a Creative Commons Attribution-NonCommercial 4.0 International License (CC BY-NC 4.0).

Introduction

Ovarian hyperstimulation syndrome (OHSS) is a iatrogenic complication of assisted reproduction techniques (ART) caused by an excessive response to controlled ovarian stimulation. Symptoms may vary, depending on the severity, from abdominal discomfort and nausea to severe dyspnea and shock, and can lead to death. This report describes a newly pregnant patient with no other risk factors for OHSS, presenting to the emergency department (ED) with dyspnea. Using Point of care Ultrasound (POCUS), she has been safely and promptly diagnosed an isolated pleural effusion.

Case Report

A 36-year-old-woman came to the ED complaining of shortness of breath that developed gradually over the past 7 days, associated during the last 48 hours with tachycardia as well as mild epigastric discomfort. She had no medical history except for an ART in the past weeks. The basal follicle count and the Anti Mullerian Hormone (AMH) values resulted normal, while the ovarian stimulation obtained less than 20 oocytes. The only two risk factors for OHSS were that she had been triggered by Human Chorionic Gonadotropin (HCG) and she had undergone embryo transfer 9 days before coming to the ED, which successfully resulted in pregnancy. Her vital signs included a normal blood pressure and an oxygen saturation of 99% when breathing room air, a heart rate of 115 beats/min and respiratory rate of 22 breaths/min. Her temperature was normal. On the physical examination she appeared slightly anxious. Her peripheral perfusion appeared to be normal, with capillary refill time of less than 2 seconds and warm and dry skin limbs, with no edema. The heart sounds were normal, without murmurs or gallop, while the pulmonary auscultation revealed an abolished vesicular murmur of the right lung. The abdomen, slightly distended, didn't present signs of ascites and bowel movements were normal. An electrocardiogram documented a sinus tachycardia, while a venous

blood gases sample was obtained, with normal results. POCUS revealed a massive unilateral right pleural effusion (Figure 1) as well as a moderate amount of abdominal free fluid mostly located in the pelvis, where two extrauterine dishomogeneous masses filled with cystic formations were visible (Figure 2). Cardiac function was normal, and no pericardial fluid was detected.

The blood tests ruled out hepatic and kidney failure, as well as clear signs of infection. At this point, gynecological referral has been set up. A transvaginal ultrasound, performed by the specialist, confirmed an intrauterine pregnancy and identified the extrauterine masses as enlarged ovaries (measuring approximately 8cm and 7cm) with multiple hemorrhagic follicles.

A diagnosis of severe ovarian hyperstimulation syndrome was made and a 20Fr chest tube was promptly positioned by the thoracic surgery team, evacuating 3 liters of serous fluid and quickly improving the symptoms. Pleural effusion and ascites were monitored by POCUS. The chest tube could be removed after 16 days, when the patient was discharged home. Approximately one month later, she came back to the ED for an acute ovarian torsion, another complication of OHSS, being successfully treated with laparoscopic detorsion surgery and quickly discharged. Her pregnancy since then was normal, and she delivered a healthy newborn.

Discussion

Infertility affects almost 50 million people worldwide, with a stable incidence documented among the last 20 years, while the use of ART is constantly increasing in the occidental countries. Natural cycle in-vitro fertilization is theoretically possible but it is associated with low pregnancy rates. For this reason, during an ART cycle, a controlled ovarian stimulation is usually induced by administering exogenous follicle-stimulating hormone (FSH) or HCG prior to oocyte retrieval, with the goal of maximizing high quality oocytes. Once the desired count is achieved, a patient is then “triggered” to initiate the ovulatory cascade that leads to the final follicle maturation process. While ART is considered safe, about one third of the patients are expected to develop some symptoms related to OHSS, a iatrogenic complication caused by an excessive response to controlled ovarian stimulation.¹ In some cases (1 to 10% of women, depending on the studies) OHSS can develop severe systemic symptoms, leading to significant morbidity and mortality. Many risk factors have been described for OHSS: i) Demographic factors. Age and body mass index (BMI) play significant roles in OHSS risk. Young age, particularly those under 30, is identified as a demographic factor associated with higher susceptibility. Similarly, a low BMI contributes to the risk profile. Individuals with polycystic ovary syndrome face an elevated risk, as do those with a history of atopy or allergies. Afro-American ethnicity is also listed as a demographic factor to consider; ii) High ovarian reserve markers, such as a history of previous OHSS, a basal anti-Müllerian hormone level exceeding 3.36 ng/mL, or a basal follicle count surpassing 24, further increases the likelihood of OHSS; iii) Ovarian stimulation. During the ovarian stimulation phase of fertility treatments, certain factors come into play. A high follicle count, defined as more than 20, significantly raises the risk of OHSS. Monitoring estradiol levels is crucial, with a rapid increase beyond 3,500 pg/mL signaling an elevated risk. If the number of oocytes retrieved exceeds 20, it is considered another potential risk factor. Moreover, the use of high or repeated doses of HCG for follicle maturation amplifies the risk during this phase; iv) After embryo transfer. After embryo transfer, specific considerations influence OHSS risk. The use of HCG in the luteal phase, a crucial aspect of many fertility protocols, is noted as a potential

contributor to OHSS risk. Additionally, the occurrence of pregnancy itself is a factor to be mindful of in relation to OHSS.

The pathophysiology of OHSS is centered on the overproduction of vasoactive substances from the hyperstimulated ovaries, that cause arteriolar vasodilation and increase capillary permeability, resulting in intravascular volume shifting to the extravascular space. This can express clinically with a variety of symptoms, from mild abdominal swelling to severe systemic involvement such as hypovolemia, renal and hepatic dysfunction, electrolyte imbalance, ascites, pleural and pericardial effusions, shock and lastly, thromboembolic events.² Other known complications of OHSS are related to the ovary raised dimension: enlarged ovaries can undergo rupture, leading to bleeding and ovarian torsion. The severity of OHSS can be determined based on both clinical presentation and blood test results. Mild OHSS is characterized by symptoms such as abdominal discomfort, nausea/vomiting, mild dyspnea, and diarrhea. Notably, blood tests conducted at this stage typically show normal values, estab-

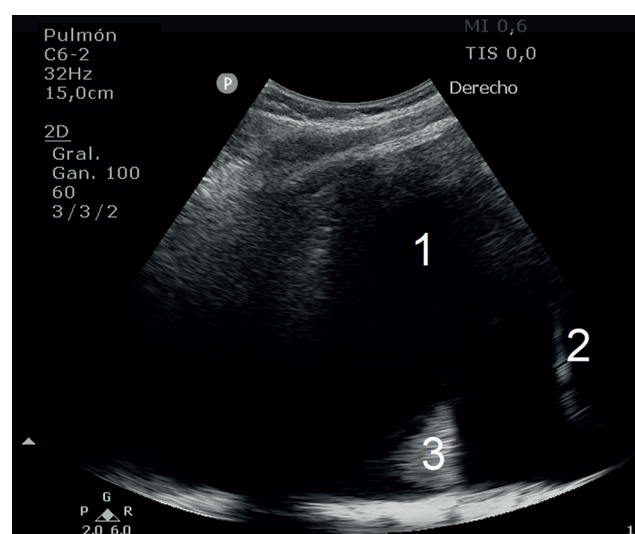


Figure 1. Massive pleural effusion (1), diaphragm (2), floating lung (3). Coronal view.

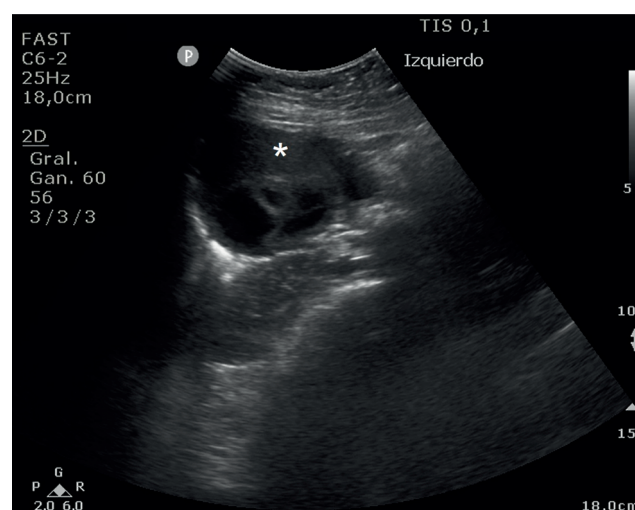


Figure 2. Hyperstimulated ovary (*) longitudinal median view.

lishing a baseline for further assessment. As OHSS progresses to the moderate stage, additional signs become apparent. In addition to the symptoms of mild OHSS, ultrasound may reveal ascites, indicating fluid accumulation in the abdominal cavity. Despite these developments, blood test results continue to fall within the normal range during this stage. The severe form of OHSS represents a critical medical condition that necessitates immediate attention. Patients experiencing severe OHSS may exhibit clinically evident ascites, where fluid accumulates not only in the abdominal cavity but also in the chest (hydrothorax), leading to severe dyspnea and oliguria. Blood tests conducted at this stage may reveal various abnormalities, including a hematocrit level exceeding 45%, a white blood cell count surpassing 15,000/mL, a glomerular filtration rate below 50 mL/min, creatinine levels exceeding 1.2 mg/dL, sodium (Na⁺) levels falling below 135 mEq/L, potassium (K⁺) levels exceeding 5 mEq/L, and a notable increase in AST/ALT levels.³

Pleural effusion occurs in severe OHSS and is usually accompanied with significant ascites, although it is reported to have occasionally been the only clinically significant manifestation of the disease.¹⁻⁴ Some theories propose that the free abdominal fluid due to the increased vascular permeability shift to the pleural space by ascending to the chest due to its negative pressure, through the thoracic duct or defects in the tendon diaphragm. The safest and quicker way to detect ascites, pleural and pericardial effusions as well as to guide their puncture is POCUS, a technique that is radiation free, portable, fast and has a steep learning curve.⁵⁻⁷ It is important to highlight that the patient in this case identified a low-risk profile for OHSS, having just two risk factors: triggering with HCG and pregnancy, which made the diagnosis unexpected. Another aspect of note is the singularity of the symptoms, since an isolated pleural effusion is an atypical presentation. With such symptoms, other potential conditions such as pneumonia or pulmonary embolism should be considered in the differential diagnosis. Typically, these conditions require imaging studies involving radiation exposure, such as chest X-rays or Computed Tomography. The utilization of POCUS allowed us to effectively rule out pneumonia and facilitated a safe and radiation-free diagnostic process and subsequent follow-up. The presence of an alternative diagnosis and the complete resolution of symptoms following the provided treatment, indeed, supported the exclusion of pulmonary embolism. The successful management of this case was made possible through a multidisciplinary collaboration, with the involvement of specialists from gynecology and thoracic surgery, ensuring a comprehensive assessment and a tailored care plan.

Conclusions and take home messages

OHSS is a quite frequent complication of ART. It relates to an increase of capillary permeability resulting in volume shift from vascular to the extravascular space, generally in form of ascites but occasionally as pleural effusion. In severe cases, patients can come to the ED presenting systemic symptoms so, even if OHSS is a typical gynecological pathology, the emergency physician must know very well this entity which incidence is increasing. An early diagnosis is essential to prevent the progression to a more severe form and to promptly treat complications. In this peculiar case, dealing with a patient at low risk for OHSS that came to the ED with mild respiratory symptoms justified by an atypical presentation of the disease (isolated pleural effusion), POCUS has been a crucial tool to guarantee an early diagnosis and a safe follow-up, without exposing a pregnant woman to unnecessary radiations.

References

1. Irani M, Robles A, Gunnala V, et al. Unilateral pleural effusion as the sole clinical presentation of severe ovarian hyperstimulation syndrome: a systematic review, *Gynecol Endocrinol* 2018;34:92-9.
2. Timmons D, Montrieff T, Koyfman A, Long B. Ovarian hyperstimulation syndrome: A review for emergency clinicians. *Am J Emerg Med* 2019;37:1577-84.
3. Navot D, Bergh PA, Laufer N: Ovarian hyperstimulation syndrome in novel reproductive technologies: prevention and treatment. *Fertil Steril* 1992;58:249-61.
4. Castillo I, García-Lozano JC, Guisado-Fernández J, et al. Derrame pleural unilateral como única manifestación del síndrome de hiperestimulación ovárica en el contexto de un tratamiento de fecundación in vitro. *Ginecol Obstet Mex* 2021;89:343-9.
5. Volpicelli G, Elbarbary M, Blaivas M, et al. International Liaison Committee on Lung Ultrasound (ILC-LUS) for International Consensus Conference on Lung Ultrasound (ICCLUS). International evidence-based recommendations for point-of-care lung ultrasound. *Intensive Care Med* 2012;38:577-91.
6. Zanforlin A, Giannuzzi R, Nardini S et al. The role of chest ultrasonography in the management of respiratory diseases: document I. *Multidiscip Respir Med* 2013;8:54.
7. Bellapu S, Guttman J. Use of Point-of-Care Ultrasound for the Diagnosis of Ovarian Hyperstimulation Syndrome. *J Emerg Med* 2017;52:e101-e104.