

Efficacy of ultrasound-guided erector spinae plane block *versus* transversus abdominis plane block for intraoperative and postoperative pain control in total laparoscopic hysterectomy: results of the ARTEMIDE randomised controlled trial

Chiara Rosato,¹ Domenico P. Santonastaso,¹ Alice Maltoni,² Annabella De Chiara,¹ Luca Mezzatesta,¹ Serena Solfrini,³ Martina Rossi,³ Patrizio M. Antonazzo,³ Federico Spelzini,⁴ Emanuele Russo,¹ Emiliano Gamberini,² Vanni Agnoletti¹

¹Anesthesia Unit, Bufalini Hospital, Cesena; ²Anesthesia Unit, Infermi Hospital, Rimini; ³Gynecology and Obstetrics Unit, Bufalini Hospital, Cesena; ⁴Gynecology and Obstetrics Unit, Infermi Hospital, Rimini, Italy

Correspondence: Chiara Rosato, Anesthesia Unit, Bufalini Hospital, Viale Ghirelli 286, 47521 Cesena (FC), Italy.
Tel.: +39.0547.352818; Fax: +39.0547.645008.
E-mail: chiara.rosato@auslromagna.it

Key words: ESP BLOCK; pain; analgesic effectiveness; anesthetic spread.

Contributions: CR: project administration, conceptualisation, methodology, investigation, writing—original draft, and supervision. DPS: investigation, writing - review and editing, visualisation, supervision. AM: project administration and investigation. ADC: validation, investigation, and resources. LM: conceptualisation and data curation. SS, MR, PMA, FS: resources. ER: software, formal analysis, writing, review, and editing. EG and VA: supervision. All authors critically revised the manuscript and approved the final version for submission.

Conflict of interest: the Authors declare no conflicts of interest.

Ethics approval and consent to participate: the Ethics Committee of AUSL Romagna approved this study (2909). The study is conformed with the Helsinki Declaration of 1964, as revised in 2013, concerning human and animal rights.

Informed consent: all patients participating in this study signed a written informed consent form for participating in this study.

Patient consent for publication: written informed consent was obtained from a legally authorized representative(s) for anonymized patient information to be published in this article.

Availability of data and materials: all data generated or analyzed during this study are included in this published article.

Received: 1 April 2023.

Accepted: 24 April 2023.

Publisher's note: all claims expressed in this article are solely those of the authors and do not necessarily represent those of their affiliated organizations, or those of the publisher, the editors and the reviewers. Any product that may be evaluated in this article or claim that may be made by its manufacturer is not guaranteed or endorsed by the publisher.

©Copyright: the Author(s), 2023

Licensee PAGEPress, Italy

Advances in Anesthesia and Pain Medicine 2023; 1:13

doi:10.4081/aapm.13

This work is licensed under a Creative Commons Attribution-NonCommercial 4.0 International License (CC BY-NC 4.0).

Abstract

Laparoscopic hysterectomy (LH), one of the most common surgeries among women, results in moderate-to-severe postoperative pain. The use of the transversus abdominis plane (TAP) block for pain management in LH has been evaluated but with conflicting results. The erector spinae plane (ESP) block has emerged as an effective and safe technique for relieving visceral pain. This study aimed to compare the analgesic efficacy of posterior TAP block *versus* ESP block following LH. We conducted a prospective, randomised, multicentre study. Seventy-six patients (American Society of Anesthesiologists I–III) scheduled for elective LH were included in the final analysis. The interventions performed were posterior TAP block (TAP group) and ESP block at T8 (ESP group). We adopted numerical rating scale (NRS) scores for pain at different time points, intraoperative remifentanyl need, rescue analgesic requirements, incidence of postoperative nausea and vomiting in the first 36 postoperative hours, and days of hospitalisation as criteria of evaluation. At nearly all time points, NRS scores did not significantly differ between the TAP and ESP groups. The TAP group had higher NRS scores for pain in the immediate postoperative period ($p=0.008$). The need for intraoperative remifentanyl was higher in the TAP group ($p=0.0018$). When needed, remifentanyl was infused at slower maximum infusion rates in the ESP group than in the TAP group (mean±SD: 0.02 ± 0.04 vs. 0.04 ± 0.05 , respectively; $p=0.006$). The total rescue analgesic requirements in the first 36 postoperative hours did not significantly differ between the two groups. We conclude that following LH, the posterior TAP and ESP blocks can achieve similar levels of pain management.

Introduction

Hysterectomy is one of the most common major surgical procedures performed in women.

The laparoscopic approach is increasingly used because it is associated with reduced postoperative pain and morbidity, as well as earlier recovery and a shorter hospital stay than open hysterectomy.¹ During total laparoscopic hysterectomy (LH), intraoperative access is achieved via small keyhole incisions in the abdominal wall or vagina (vaginal natural orifice transluminal endoscopic surgery [vNOTES]). Incisional and trocar-site pain are the most important sources of pain. In addition, the head-down

position and pneumoperitoneum during surgery, stretching of the intra-abdominal cavity, blood left in the abdomen, and dissection of the pelvic region may aggravate pain.^{2,3} Women are more likely to report higher levels of postoperative pain than men,⁴ and female patients undergoing laparoscopic surgery are at high risk for postoperative nausea and vomiting (PONV), with an incidence as high as 80%.⁵ Pain associated with hysterectomy can also worsen the patient's outcome and prolong the duration of hospitalisation.⁶

Healthcare institutions are increasingly developing enhanced recovery after surgery (ERAS) protocols to improve perioperative clinical outcomes and early surgical recovery. A key tenet of ERAS protocols is the optimisation of postoperative pain control using a multimodal approach to reduce opioid use as the primary analgesic.⁷ The delivery of non-opioid medications via neuraxial and peripheral regional anaesthesia is highly useful for ensuring optimal pain control, efficiency, and patient satisfaction and reducing the incidence of adverse effects related to opioid use, such as PONV.^{8,9}

Neuraxial blocks can produce surgical anaesthesia and dense postoperative analgesia; however, considering the associated risks, they are not routinely indicated in minimally invasive gynaecological surgery.

Recently, regional techniques have been developed to address pain after gynaecological laparoscopic surgery while avoiding the potential complications associated with neuraxial techniques. Current options include quadratus lumborum block (QLB), paracervical block, transversus abdominis plane (TAP) block, erector spinae plane (ESP) block.^{10,11}

The TAP block targets the innervation of the anterior abdominal wall: the subcostal, iliohypogastric, and ilioinguinal nerves through the lumbar triangle of Petit, between the transversus abdominis and internal oblique muscles.¹² The goal of the block is to inject the local anaesthetic (LA) in the plane between these muscles using a midaxillary/lateral, posterior, subcostal, or oblique/subcostal approach to induce analgesia in the abdominal wall. TAP blocks have been shown to decrease opioid consumption for the first 24 h following open hysterectomy.^{13,14} Several studies have also evaluated the use of TAP blocks for pain management in LH; however, their results have conflicted.^{15,16} As surgical practice continues to become less invasive, the value of the TAP block for minimally invasive gynaecologic surgery remains unclear.¹⁷

The effects of the ESP block are likely due to the spread of the LA into the thoracic paravertebral space, which targets the ventral rami, dorsal rami, and rami communicantes of the spinal nerves, thereby providing analgesia to the anterior, posterior, and lateral thoracic and abdominal walls. However, the mechanisms by which the LA spreads and exerts these effects have not been fully elucidated.¹⁸

Several authors have reported preliminary clinical evidence regarding the use of bilateral ESP blocks for postoperative analgesia following laparoscopic abdominal surgery.^{19,20} However, few studies have investigated the value of the ESP block for pain management after LH.²¹ Accordingly, regional anaesthesia techniques are not routinely used as prophylactic pain measures in patients undergoing laparoscopic gynaecological surgery given the lack of consistent evidence that this procedure has a sustained effect on postoperative pain.

While the current literature suggests that each technique may offer some clinical benefits, the criteria for selecting one technique over another also remain unclear. In the current study, we aimed to compare the effects of ultrasound-guided bilateral posterior TAP block and bilateral ESP block on intra- and postoperative pain control in patients undergoing total LH.

Our primary endpoint was the NRS pain score at different time points. The secondary endpoints were intraoperative remifentanyl

need, total rescue analgesic requirement, and incidence of PONV or any other complications in the first 36 postoperative hours.

Materials and Methods

Study design

This prospective, randomised, controlled study was conducted at the Bufalini Hospital in Cesena, Italy and the Infermi Hospital in Rimini, Italy. The study was approved by the ethics committee of the local health authority and was conducted in accordance with the principles outlined in the Declaration of Helsinki. The trial was registered prior to patient enrolment at ClinicalTrials.com (Trial ID: NCT04839445).

Patients aged between 18 and 85 years with American Society of Anesthesiologists (ASA) physical status I–III who were scheduled for elective total LH with or without salpingo-oophorectomy or lymphadenectomy were included in the study. All patients underwent LH for benign (symptomatic uterine fibroids or adenomyosis) or malignant indications (endometrial cancer). Each patient signed an informed consent form for block intervention and participation in the study. The exclusion criteria were the presence of infection at the block injection site, known allergy to the drugs used in the study, chronic opioid consumption, and body mass index (BMI) ≥ 40 .

Patient randomization

The patients were randomly assigned to two groups (TAP and ESP) based on a computerised randomisation table created by a researcher who was not involved in the study.

For each randomised patient, the operating room (OR) anaesthesiologist took the corresponding sealed envelope from a folder, which indicated the treatment to be assigned to the patient.

Anaesthesia application

Before induction of general anaesthesia (GA), standard monitoring of electrocardiography parameters, non-invasive blood pressure (BP), peripheral oxygen saturation, and the bispectral index (BIS, Covidien Medtronic, Minneapolis, MN, USA) were performed on all patients. Baseline vital signs were recorded following placement of the intravenous line.

For GA induction, remifentanyl was supplied as totally intravenous anaesthesia (TIVA), while intravenous propofol was infused at a rate of 2.5 mg/kg/h. After the placement of a “train of four” monitoring device (TOFscan, Dräger, France, FR, UE) for the measurement of neuromuscular transmission, a bolus of intravenous rocuronium (0.6 mg/kg) was administered, and orotracheal intubation (IOT) was performed. The remifentanyl infusion was stopped after IOT.

GA was maintained via TIVA with propofol, and the infusion rate was adjusted according to the BIS values (ranging from 40 to 60). The preferred ventilatory settings for protective ventilation were set to a tidal volume of 6–8 mL/kg, and the target respiratory rate was selected to achieve end-tidal carbon dioxide (etCO₂) values less than or equal to 40 mmHg.

If BP and/or heart rate (HR) values exceeded pre-operative baseline values by 20%, patients received additional intravenous remifentanyl via infusion at 0.02 µg/kg/min, as well as infusion rate corrections of ± 0.02 µg/kg/min according to clinical needs. Additional intravenous rocuronium (0.1 mg/kg) was administered based on clinical needs and TOF monitoring. An analgesic starter of intravenous acetaminophen (1 g) and ketorolac (30 mg) was administered 30 min before the end of the surgery.

Locoregional anaesthesia and surgical techniques

Ultrasound guidance (SonoSite M-Turbo, SonoSite Inc., Bothell, WA, USA) with a 16-6 MHz linear probe and a 22-G x 85-50 mm needle (Echoplex+, Vygon, Ecouen, France) was used for both blocks in all patients. Both blocks were performed with a sterile technique using hydrolocation with 0.9% saline to visualise the position of the needle tip. The drugs used for both blocks were identical: a blend of ropivacaine 0.37% (20 mL) and dexamethasone at 2 mg (0.5 mL) per side (41 mL total). Both blocks were performed with expert anesthetists.

Patients in the TAP group received a posterior TAP block in the supine position after GA induction, 20 minutes before the start of surgery. The ultrasound probe was placed between the iliac crest and costal margin, and the TAP was identified. The probe was then moved posteriorly following the fascial plane between the internal oblique and transversus abdominis muscles. The posterior border of the TAP was also identified. An 85-mm needle was inserted in the midaxillary line and advanced in the posterior direction using an in-plane technique until the tip reached the end of the TAP, such that the drug injected was located at approximately the intersection of the quadratus lumborum and the lateral abdominal muscles, superficial to the transversalis fascia. The same procedure was repeated for the contralateral side.

Patients in the ESP group received an ESP block in the lateral decubitus position 20 min before GA induction. The ultrasound probe was placed in a longitudinal orientation at the level of the T8 spinous process and then moved laterally from the midline until the main ultrasound landmark (T8 transverse process and overlying erector spinae muscle) had been identified. A 50-mm needle was inserted using the out-of-plane approach until the needle tip came into contact with the transverse process, such that the injected drug spread, separating the erector spinae muscle from the transverse process. The same procedure was repeated for the contralateral side.

Surgeries were performed in accordance with standard procedures using a 10-mm laparoscope (Karl Storz, Germany) inserted through a disposable 12-mm trocar placed by optical access in the umbilicus. Two lateral 5-mm trocars were placed along the suprapubic line. The third trocar was placed at the suprapubic midline.

A uterine manipulator (HOHL, Karl Storz, Germany) was placed before the procedure.

The specimen was removed from the toto when uterine size allowed it. When needed, morcellation was performed by hand using scissors or a scalpel to remove small pieces of the specimen through the vagina or by in-bag vaginal morcellation (Endo Catch; Medtronic, Milano, Italy).

Vaginal cuff closure was usually performed laparoscopically with an interrupted polyglactin 2.0 suture and intracorporeal knots. After vaginal in-bag morcellation, suturing was performed vaginally. When the uterus was too large to fit the endobag, the specimen was removed via a small transverse incision in the lower abdominal wall by enlarging the median suprapubic incision using a wound protector/retractor (Alexis, Applied Medical, Rancho Santa Margarita, USA).

Postoperative analgesia and evaluation of pain

Intravenous acetaminophen (1 g) was administered every 8 hours from the first intraoperative dose. An 11-point NRS was used to assess the subjective intensity of postoperative pain in both groups, with 0 indicating “no pain” and 10 indicating the “worst pain imaginable”.

The NRS scores were recorded immediately postoperatively (0 min) and at 2, 6, 12, 24, and 36 h by an anaesthesiologist who was blinded to the group allocation.

In the immediate postoperative period, intravenous morphine (2 mg) was administered when the NRS score for pain exceeded 4. When such treatment was unsuccessful, another 2 mg of intravenous morphine was administered, up to a maximum of 10 mg.

In the surgical ward, intravenous ketorolac (30 mg) was administered as rescue analgesia whenever the NRS exceeded 4 or was on-demand for a maximum of 3 times a day (1 step=30 mg IV ketorolac). If pain exceeded an NRS score of 4 30 min after ketorolac administration, 2 mg of intravenous morphine was administered (2 steps=IV ketorolac 30 mg + IV morphine 2 mg).

If the pain therapy was still unsuccessful, another 2 mg of intravenous morphine was administered for a maximum of 10 mg/day.

The first-line treatment for PONV consisted of intravenous ondansetron 4 mg twice a day as needed; if this proved ineffective, second-line therapy consisted of intravenous metoclopramide (10 mg) as needed.

Outcome measures

Our primary endpoint was the NRS pain score at different time points. The secondary endpoints were intraoperative remifentanyl need, total rescue analgesic requirements, and incidence of PONV or any other complications in the first 36 postoperative hours.

Patient satisfaction with the anaesthetic procedure used was evaluated and recorded 36 hours after surgery on a 7-point Likert scale (1=extremely dissatisfied, 2=very dissatisfied, 3=dissatisfied, 4=neither satisfied nor dissatisfied, 5=satisfied, 6=very satisfied, 7=extremely satisfied). Each patient was discharged when deemed safe, based on the Italian version of the post-anesthesia discharge scoring system (PADS), and the total duration of hospitalisation in days was recorded.

Sample size calculation

The sample size was calculated based on a pilot study of 10 patients in each group. Using the change in the NRS score for pain at 6 h after surgery as the primary endpoint, approximately 50% of patients in the TAP group had achieved NRS scores of 4, while this percentage reached 80% in the ESP group. Given this difference, 39 patients were required in each group (allocation ratio 1:1) to ensure a power of 80%, with a type I error of 5%. To account for the possibility of dropout, we chose to include at least 42 patients per group. Sample size calculation was performed using the software STATA 14.2 for Windows.

Statistical analysis

Data are reported as mean with standard deviation (SD), median with interquartile range (IQR), number, and percentage, depending on the underlying distribution. Differences between the two groups were examined using the t-test or Mann-Whitney U-test according to the characteristics and distribution of the variables. Fisher's exact test was used for categorical variables. Statistical analysis was performed using the software IBM SPSS 22.0. The level of statistical significance was expressed as a p-value ≤ 0.05 .

Results

In total, 84 patients (all women) were screened for enrolment in the study. After the exclusion of three patients (BMI ≥ 40 , n=2; chronic opioid consumption, n=1), 81 patients were included in the randomisation process. Following randomisation, five patients were excluded due to reversion of the surgical technique to an open approach. Consequently, 76 patients completed the study (Figure 1).

There were no significant differences in age, BMI, Apfel scores for PONV, or ASA risk between the groups. The detailed characteristics of the patients are listed in Table 1.

Seventeen patients underwent total LH: 11 in the TAP group (28.9%) and 6 in the ESP group (15.8%). Fifty-two patients also underwent salpingo-oophorectomy: 24 in the TAP group (63.2%) and 28 in the ESP group (73.7%). Seven patients underwent lymphadenectomy (pelvic lymph nodes): three in the TAP group (7.89%) and four in the ESP group (10.5%). In four cases (3 TAP, 1 ESP), the uterus was too large to enter the endobag, so the

specimen was removed by enlarging the suprapubic incision. There were no differences in the distribution of surgical types between the two groups.

Surgery was completed within a time range of 60–420 minutes, with an average of 120 minutes (standard deviation, SD ± 59.97) for the TAP group and 130 minutes for the ESP group (± 68.99).

At all measurement points, the mean and median NRS scores less than 4 in both groups. At nearly all time points, NRS scores did not significantly differ between the groups (Table 2).

In line with repeated measures analysis, integration of the

Table 1. Patient characteristics in each group.

Characteristics	Total (Mean)	TAP Group (Mean \pm SD)
Age (years)	55.15	53.73 \pm 10.59
BMI (kg/m ²)	25.51	25.48 \pm 4.80
ASA I/II/III (%)	11/51/14 (14.5/67.1/18.4)	8/25/5 (21.1/65.8/13.2)
Apfel score 1/2/3 (%)	17/50/9 (22.4/65.8/11.8)	6/27/5 (15.8/71.1/13.2)

SD, standard deviation; BMI, body mass index; ASA, American society of Anesthesiologists; TAP, transversus abdominis plane; ESP, erector spinae plane.

Table 2. Comparison of NRS pain scores in each group.

NRS Score	TAP Group (Mean \pm SD)	ESP Group (Mean \pm SD)	P-value
0 min	3.21 \pm 2.17	2.07 \pm 1.97	0.008
2 h	1.60 \pm 1.74	1.39 \pm 1.63	0.535
6 h	1.63 \pm 1.21	1.52 \pm 1.53	0.401
12 h	1.10 \pm 1.35	0.97 \pm 1.34	0.606
24 h	0.71 \pm 1.35	0.36 \pm 1.05	0.166
36 h	0.18 \pm 0.56	0.10 \pm 0.50	0.405

NRS, numerical rating scale; h, hour; SD, standard deviation; TAP, transverse abdominal plane; ESP, erector spinae plane.

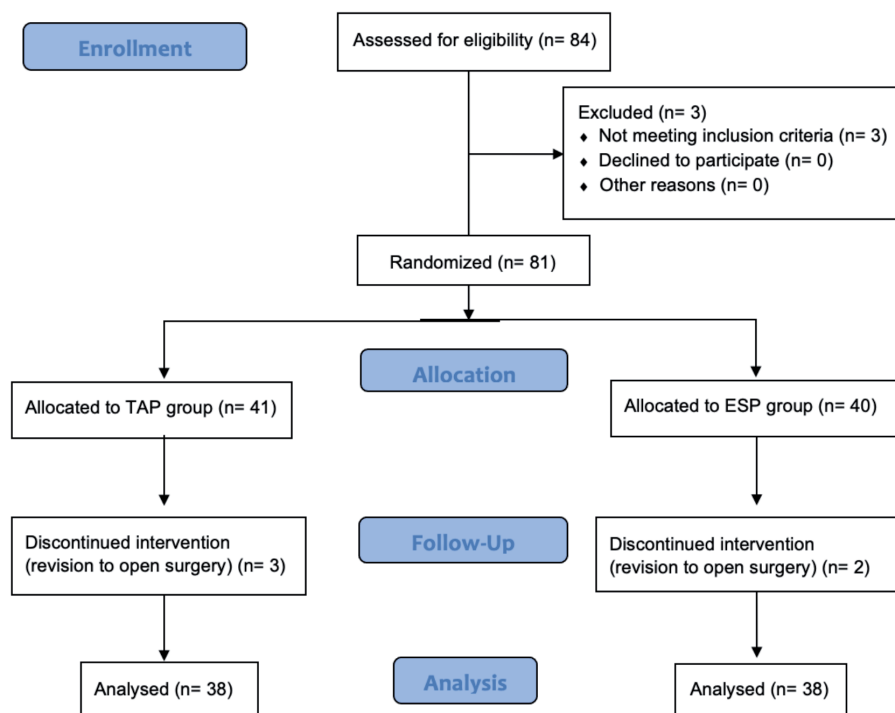


Figure 1. Flowchart of the study. TAP: transverse abdominal plane; ESP: erector spinae plane.

Mann–Whitney U-test results revealed that there was a difference in the distribution of NRS scores between the groups in the immediate postoperative period (NRS 0 min), suggesting that the TAP group had a higher NRS ($p=0.008$) (Figure 2).

The intraoperative remifentanyl need differed significantly between the two groups, with 52.6% of patients in the TAP group requiring additional intravenous remifentanyl *versus* 18.4% of patients in the ESP group ($p=0.0018$). When needed, remifentanyl was infused at slower maximum infusion rates in the ESP group than in the TAP group (mean \pm SD: 0.02 ± 0.04 vs. 0.04 ± 0.05 , respectively; $p=0.006$).

When needed at awakening, morphine was administered at doses that were not significantly different between the two groups and were less than or equal to 4 mg in 90.79% of the total cases.

In the surgical ward, morphine was administered as a rescue analgesic only three times and did not exceed the dosage of 2 mg in either group. Morphine was not administered after the first 6 postoperative hours, and the total rescue analgesic consumption in the first 36 postoperative hours did not significantly differ between the two groups (Table 3).

In the immediate postoperative period, two episodes of PONV were observed in the TAP group (5.26%), both of which resolved following administration of intravenous ondansetron at 4 mg. Of the four episodes of PONV in the ESP group (10.5%), one resolved without the use of antiemetic drugs, and the other three resolved following administration of intravenous ondansetron at 4 mg. No other episodes of PONV were observed in either group during hospitalisation.

No patients in the TAP group and only one patient in the ESP group experienced hypotension, and there was no significant differences between the groups (chi-square=1.01, $p=0.31$). Intraoperative bradycardia was observed in two patients (5.26%) in the TAP group and four patients (10.5%) in the ESP group, with no significant difference between the groups (chi-square=0.72, $p=0.39$). No other intraoperative complications were noted.

There was no significant difference in the duration of hospitalisation, which was 2.5 days on average in both groups ($p=0.44$). All patients expressed high satisfaction with the anaesthesiologic procedure (always greater than 5, according to the

scale mentioned in Subsection 2.6). No complications occurred during the execution of either block.

Discussion

To the best of our knowledge, this is the first trial to evaluate the efficacy of ultrasound-guided ESP block *versus* TAP block for intraoperative and postoperative pain control in LH. The success of this technique in a case²² and experience with a few subsequent cases prompted us to initiate this randomised controlled study.

In the current study, NRS scores were nearly the same in both groups at all the time points except in the immediate postoperative

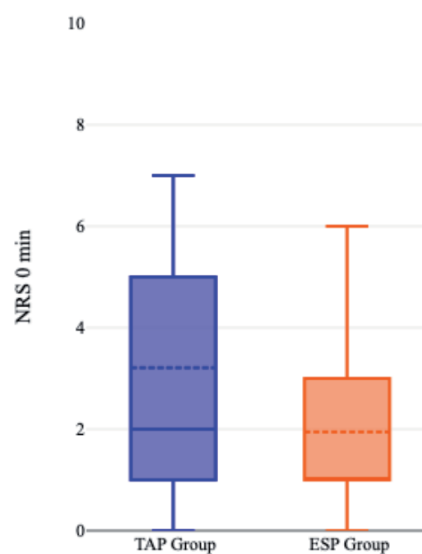


Figure 2. Boxplot. TAP: transverse abdominal plane; ESP: erector spinae plane.

Table 3. Intraoperative and postoperative analgesic requirements.

	TAP Group	ESP Group	P-value
Additional remifentanyl need (maximum infusion rates) (Mean \pm SD) (mcg/kg/min)	0.04 \pm 0.05	0.02 \pm 0.04	0.006
Rescue (Morphine) analgesic requirements (Mean \pm SD) (mg), 0 min	1.73 \pm 3.15	0.78 \pm 1.57	0.184
Rescue analgesic requirements, 2 h	0 step=86.8% 1 step=7.89% 2 steps=5.26%	0 step=84.2% 1 step=15.8% 2 steps=0%	0.221
Rescue analgesic requirements, 6 h	0 step=92.1% 1 step=5.26% 2 steps=2.63%	0 step=86.8% 1 step=13.2% 2 steps=0%	0.309
Rescue analgesic requirements, 12 h	0 step=92.1% 1 step=7.89% 2 steps=0%	0 step=92.1% 1 step=7.89% 2 steps=0%	1.00
Rescue analgesic requirements, 24 h	0 step=89.5% 1 step=10.5% 2 steps=0%	0 step=92.1% 1 step=7.89% 2 steps=0%	0.691
Rescue analgesic requirements, 36 h	0 step=100%	0 step=100%	

SD, standard deviation; 0 step, no rescue analgesic required; 1 step, iv ketorolac 30 mg; 2 steps, iv ketorolac 30 mg+morphine 2 mg; TAP, transverse abdominal plane; ESP, erector spinae plane.

period (NRS 0 min), where the TAP group had a higher NRS. The intraoperative remifentanyl need differed significantly between the two groups, with a significant proportion of the TAP group's patients requiring additional remifentanyl, at higher average infusion rates.

Ultrasound-guided TAP block is a well-known analgesic technique with highly variable patterns of local anaesthetic spread. The efficacy of TAP block is still debated today, likely due to the high heterogeneity of the surgical interventions in which it is applied and the approaches with which it is performed, as well as the volume of LA used.^{23,24}

Several previous studies reported that posterior TAP block produces a sensory block affecting not only the somatic and parietal components of postoperative pain but also the visceral components when compared with other approaches, probably due to posterolateral spread of the local analgesic agent to the paravertebral space. Moreover, LA also provides systemic analgesia, as it is transported along the vascular and lymphatic systems.^{25,26} However, these considerations are in contrast with those reported in a narrative review by Jones *et al.*,²⁷ where they concluded that precisely because of the variable patterns of anaesthetic spread, the approach should be chosen based on the type of surgery, and if visceral pain is expected it is better to opt for ESP blocks.

The differences in intraoperative remifentanyl requirements and NRS scores at 0 min observed in the current study are likely related to the longer time required for the TAP block to spread posterolaterally to the target. This spread is directed to the paravertebral space and is delegated to cover the visceral component of pain, which is more prominent in the intraoperative period during dissection of the pelvic surgical planes.

Meta-analyses and randomised controlled trials (RCT) comparing TAP block with placebo or no block have yielded conflicting results with moderate quality of evidence, precisely because some studies analysed different surgical techniques together. For example, Bacal *et al.*¹¹ included LH and total abdominal hysterectomies in the same analysis, while other trials in which the analgesic starter and postoperative analgesia administered were very different for dosages and pharmaceutical classes. This heterogeneity emphasises the importance of multimodal management of anaesthesia and analgesia and the extent to which each individual drug contributes to the reduction of postoperative pain. The standardised anaesthetic protocol utilised in our trial was in line with the recommendations of the most authoritative scientific associations. Albeit with a small sample, the study demonstrates excellent results and a low use of morphine. This shows that many studies are still needed to explore the incredible potential of wall blocks.

Moreover, trocar placement was not specified in these previous studies, despite being an important contributor to parietal pain.^{17,28} In fact, as suggested by Kane *et al.*,²⁹ one potential reason for the failure of TAP blocks in some trials may be the localisation of port sites; depending on the size of the uterus and pathology, these may be placed at the level of and below the umbilicus or above the umbilicus, while others may require midline single-port techniques.

Therefore, lateral TAP blocks may not be optimally suited for all types of LH, and subcostal blocks may be more appropriate for patients with more cranial port insertion points.³⁰ As mentioned in Subsection 2.4, in our trial, the port insertion points were all above the umbilicus except for the 12-mm trocar placed in the umbilicus.

ESP block is certainly a “younger” technique, yet the strong interest of the scientific community has allowed for assessments of its effectiveness in various contexts. Huang *et al.*³¹ reported that ESP block is effective in reducing opioid consumption and postoperative pain, largely due to paravertebral spread. The authors analysed RCTs involving surgeries with different predominant pain

components, which were sometimes visceral and sometimes parietal. At the conclusion of the study, they noted that it is difficult to determine whether the effectiveness of ESP is more or less valid than that of the TAP block given identical pain components, thereby acknowledging that we are still far from achieving convincing conclusions.

There is little evidence in the literature supporting the use of ESP blocks in LH. Frassanito *et al.*²¹ conducted an observational study, concluding that the ESP block performed at a low thoracic level provides abdominal somatic and visceral analgesia and may be more effective than other abdominal wall blocks.

Kamel *et al.*³² compared the effects of the two blocks on postoperative pain after total abdominal hysterectomy. In their trial, the ESP block was shown to be superior in terms of analgesic coverage and duration. Similar results with nearly identical methods for anaesthesia were demonstrated by Shukla *et al.*³³

However, we cannot compare our results with those of a study focused on open surgery given that pain intensities following open and laparoscopic hysterectomy are incomparable.² Altıparmak *et al.*²⁰ compared the two blocks for postoperative analgesia in adult patients undergoing laparoscopic cholecystectomy, reporting significantly lower NRS pain scores in the ESP group at nearly all time points. Beyond the differences in the mixture of LA used and the approach of the block, the most substantial difference between the present and previous studies is related to the difference in the target organ. While gallbladder excision includes an important visceral component of pain, the visceral component of LH is probably less represented, at least in the postoperative period.

While Altıparmak *et al.*²⁰ also reported no differences in intraoperative fentanyl levels, they suggested that this may have been because intravenous fentanyl was administered during the induction of GA, and the mean surgery time was 55 min. Therefore, they encouraged further studies using remifentanyl to better detect differences in intraoperative opioid needs. In our trial, we performed GA using TIVA with propofol, and only antalgic coverage of orotracheal intubation was performed using remifentanyl. The remifentanyl infusion was then stopped to allow us to fully test the efficiency of the block, owing to the very short duration of its action.

Moreover, Altıparmak *et al.*²⁰ documented that postoperative tramadol consumption was significantly lower in the ESP group than in the TAP group at 24 h. In our trial, the total rescue analgesic consumption in the first 36 postoperative hours did not differ significantly between the two groups. While Altıparmak *et al.*²⁰ also reported no significant group differences in intraoperative or postoperative complications such as PONV, they administered a major antiemetic starter consisting of 4 mg of ondansetron and 50 mg of dexamethasone. Although we also observed no differences in the incidence of PONV, we did not administer antiemetic drugs as part of our protocol, despite the high emetic risk of the procedure. We are confident that little or no use of opioids, together with the use of propofol in TIVA with its well-known antiemetic properties, would have protected patients from this complication. The results of our study and the low amounts of morphine administered demonstrate that TAP block performed using a posterior approach and ESP block performed at a low thoracic level have opioid-sparing effects.

Several notable limitations of this study should be considered when interpreting its results. First, even with a non-significant distribution, types of surgery differed unevenly between the groups. Given the small sample size, the subgroup analysis seemed impossible to us. With the data we possess, it is not possible to increase the sample size without losing accuracy. The authors believe that removing this grouping would further reduce the small sample size without gaining any particular advantage. Second,

sensorial evaluation of the patients was not performed. Furthermore, we did not include an intervention control group. We did not include a placebo group since we did not consider it ethical to conduct a GA without analgesics. Moreover, we could have included a third study arm comparing TAP and ESP with the QLB block, as currently QLB block is the prototype block for providing both parietal and visceral analgesia in abdominal surgery. Lastly, the use of PCA instead of analgesic rescue doses on-demand may provide better-quality analgesia, and certainly it would have been useful in data collection. Unfortunately we did not have PCA for all the enrolled patients, so we did not use it and rescue doses were readily administered by nursing staff as needed. This did not appear to affect the results.

Conclusions

The current results suggest that ultrasound-guided ESP and posterior TAP blocks are comparable in terms of pain management following LH. Both blocks are easy to perform and exhibit high efficacy, a good safety profile, and allow for adequate distance between the procedure area and the operation site, without the need for a motor block. Further studies are required to evaluate the predominant component of visceral pain in this type of surgery and to evaluate the best individualised analgesic strategies for patients undergoing LH.

References

- Gendy R, Walsh CA, Walsh SR, Karantanis E. Vaginal hysterectomy versus total laparoscopic hysterectomy for benign disease: a meta-analysis of randomized controlled trials. *Am J Obstet Gynecol* 2011;204:388.e1-8.
- Choi JB, Kang K, Song MK, et al. Pain characteristics after total laparoscopic hysterectomy. *Int J Med Sci* 2016;13:562-8.
- Gerbershagen HJ, Aduckathil S, Van Wijck AJ, et al. Pain intensity on the first day after surgery: a prospective cohort study comparing 179 surgical procedures. *Anesthesiology* 2013;118:934-44.
- Caumo W, Schmidt AP, Schneider CN, et al. Preoperative predictors of moderate to intense acute postoperative pain in patients undergoing abdominal surgery. *Acta Anaesthesiol Scand* 2002;46:1265-71.
- Li HJ, Liu S, Geng ZY, Li XY. Adding dexmedetomidine to morphine-based analgesia reduces early postoperative nausea in patients undergoing gynecological laparoscopic surgery: a randomized controlled trial. *BMC Anesthesiol* 2020;20:11.
- Acton JN, Salfinger SG, Tan J, Cohen PA. Outcomes of total laparoscopic hysterectomy using a 5-mm versus 10-mm laparoscope: A randomized control trial. *J Minim Invasive Gynecol* 2016;23:101-6.
- Nelson G, Bakkum-Gamez J, Kalogera E, et al. Guidelines for perioperative care in gynecologic/oncology: Enhanced Recovery After Surgery (ERAS) Society recommendations-2019 update. *Int J Gynecol Cancer* 2019;29:651-68.
- Gritsenko K, Khelemsky Y, Kaye AD, et al. Multimodal therapy in perioperative analgesia. *Best Pract Res Clin Anaesthesiol* 2014;28:59-79.
- Geng Z, Bi H, Zhang D, et al. The impact of multimodal analgesia based enhanced recovery protocol on quality of recovery after laparoscopic gynecological surgery: a randomized controlled trial. *BMC Anesthesiol* 2021;21:179.
- Macías AA, Finneran JJ. Regional anesthesia techniques for pain management for laparoscopic surgery: A review of the current literature. *Curr Pain Headache Rep* 2022;26:33-42.
- Bacal V, Rana U, McIsaac DI, Chen I. Transversus abdominis plane block for post hysterectomy pain: A systematic review and meta-analysis. *J Minim Invasive Gynecol* 2019;26:40-52.
- Rafi AN. Abdominal field block: a new approach via the lumbar triangle. *Anaesthesia* 2001;56:1024-6.
- Carney J, McDonnell JG, Ochana A, et al. The transversus abdominis plane block provides effective postoperative analgesia in patients undergoing total abdominal hysterectomy. *Anesth Analg* 2008;107:2056-60.
- Suner ZC, Kalayci D, Sen O, et al. Postoperative analgesia after total abdominal hysterectomy: Is the transversus abdominis plane block effective? *Niger J Clin Pract* 2019;22:478-84.
- Guardabassi DS, Lupi S, Agejas R, Allub JM, García-Fornari G. Efficacy of ultrasound-guided transversus abdominis plane block in laparoscopic hysterectomy. Clinical trial. *Rev Esp Anestesiol Reanim* 2017;64:257-61. English, Spanish.
- Korkmaz Toker M, Altıparmak B, Uysal AI, Demirbilek SG. The analgesic efficacy of oblique subcostal transversus abdominis plane block after laparoscopic hysterectomy: A randomized, controlled, observer-blinded study. *Medicine (Baltimore)* 2019;98:e13994.
- Shin JH, Balk EM, Gritsenko K, et al. Transversus abdominis plane block for laparoscopic hysterectomy pain: A meta-analysis. *JSLs* 2020;24:e2020.00018.
- Chin KJ, Lirk P, Hollmann MW, Schwarz SKW. Mechanisms of action of fascial plane blocks: a narrative review. *Reg Anesth Pain Med* 2021;46:618-28.
- Yildiz M, Kozanhan B, Iyisoy MS, et al. The effect of erector spinae plane block on postoperative analgesia and respiratory function in patients undergoing laparoscopic cholecystectomy: A double-blind randomized controlled trial. *J Clin Anesth* 2021;74:110403.
- Altıparmak B, Korkmaz Toker M, Uysal AI, et al. Ultrasound-guided erector spinae plane block versus oblique subcostal transversus abdominis plane block for postoperative analgesia of adult patients undergoing laparoscopic cholecystectomy: Randomized, controlled trial. *J Clin Anesth* 2019;57:31-6.
- Frassanito L, Zanfini BA, Catarci S, et al. Erector spinae plane block for postoperative analgesia after total laparoscopic hysterectomy: case series and review of the literature. *Eur Rev Med Pharmacol Sci* 2020;24:3892-7.
- Rosato C, Santonastaso DP, de Chiara A, et al. Erector spinae plane block for pain management in laparoscopic hysterectomy and bilateral oophorectomy. *J Clin Anesth* 2021;70:110184.
- Siddiqui MR, Sajid MS, Uncles DR, et al. A meta-analysis on the clinical effectiveness of transversus abdominis plane block. *J Clin Anesth* 2011;23:7-14.
- Brogi E, Kazan R, Cyr S, et al. Transversus abdominal plane block for postoperative analgesia: a systematic review and meta-analysis of randomized-controlled trials. *Can J Anaesth* 2016;63:1184-96. English.
- Carney J, Finnerty O, Rauf J, et al. Studies on the spread of local anaesthetic solution in transversus abdominis plane blocks. *Anaesthesia* 2011;66:1023-30.
- Furuya T, Kato J, Yamamoto Y, et al. Comparison of dermatomal sensory block following ultrasound-guided transversus abdominis plane block by the lateral and posterior approaches: A randomized controlled trial. *Anaesthesiol Clin Pharmacol* 2018;34:205-210.
- Jones JH, Aldwinckle R. Interfascial plane blocks and laparoscopic abdominal surgery: A narrative review. *Local Reg Anesth* 2020;13:159-69.

28. López-Ruiz C, Orjuela JC, Rojas-Gualdrón DF, et al. Efficacy of transversus abdominis plane block in the reduction of pain and opioid requirement in laparoscopic and robot-assisted hysterectomy: A systematic review and meta-analysis. *Rev Bras Ginecol Obstet* 2022;44:55-66.
29. Kane SM, Garcia-Tomas V, Alejandro-Rodriguez M, et al. Randomized trial of transversus abdominis plane block at total laparoscopic hysterectomy: effect of regional analgesia on quality of recovery. *Am J Obstet Gynecol* 2012;207:419.e1-5.
30. Lirk P, Thiry J, Bonnet MP, et al. Pain management after laparoscopic hysterectomy: systematic review of literature and PROSPECT recommendations. *Reg Anesth Pain Med* 2019;44:425-36.
31. Huang J, Liu JC. Ultrasound-guided erector spinae plane block for postoperative analgesia: a meta-analysis of randomized controlled trials. *BMC Anesthesiol* 2020;20:83.
32. Kamel AAF, Amin OAI, Ibrahim MAM. Bilateral ultrasound-guided erector spinae plane block versus transversus abdominis plane block on postoperative analgesia after total abdominal hysterectomy. *Pain Physician* 2020;23:375-82.
33. Shukla U, Yadav U, Singh AK, Tyagi A. randomized comparative study between bilateral erector spinae plane block and transversus abdominis plane block under ultrasound guidance for postoperative analgesia after total abdominal hysterectomy. *Cureus* 2022;14:e25227.